

The Diagnosis and Management of Gallstones in the Elderly

Bao Q. Tang, MD, FRCS(C), Clinical Fellow, Minimally Invasive Surgery Program, Division of General Surgery, University Health Network, Toronto, ON.

David R. Urbach, MD, MSc, FRCS(C), Assistant Professor of Surgery and Health Policy, Management and Evaluation, University of Toronto; Staff Surgeon, Division of General Surgery, University Health Network, Toronto, ON.

Gallstone disease is common in elderly persons. The clinical syndromes caused by symptomatic gallstones include biliary colic, acute cholecystitis, acute gallstone pancreatitis, choledocholithiasis, cholangitis and gallstone ileus. In most cases, an accurate diagnosis can be made on the basis of the history, physical examination, basic blood tests and abdominal ultrasonography. Cholecystectomy is the appropriate treatment for most patients with symptomatic gallstones, and can be done safely in the elderly. Because the risk of complications of gallstone diseases is higher in the elderly than in younger patients, symptomatic gallstone disease should be identified and treated promptly in elderly persons.

Key words: *gallstones, cholecystitis, pancreatitis, cholangitis, cholecystectomy.*

Introduction

Gallstone disease is common in developed countries, occurring in 10–20% of the population, and in approximately one-third of those older than 70 years.¹ Although many individuals with gallstones do not have any symptoms and require no treatment, those patients with symptoms suggestive of gallstone disease should be investigated and subsequently treated if gallstones are present.

Compared with the management of symptomatic gallstone disease in young patients, management in the elderly is guided by three important considerations. First, elderly patients are more likely to present with complications than younger patients with symptomatic gallstones.² Second, some elderly patients with severe, life-threatening complications of gallbladder disease may present with very mild signs and symptoms. Third, although the morbidity and mortality of elective gallbladder surgery in elderly patients is similar to those in younger patients, the mortality of emergency surgery is much higher among the elderly.³ As a result, symptomatic gallstone disease should be identified and treated promptly in the elderly. Fortunately, recent advances in ther-

apeutic endoscopy and surgery have made effective treatment of symptomatic gallstones much safer than in the past.

Gallbladder Disease

Bile is a substance that facilitates the intestinal absorption of lipids and fat-soluble vitamins, and is secreted by the liver into the bile duct. The gallbladder stores bile during the fasting state, and empties it into the small intestine following ingestion of a fatty meal. Contraction of the gallbladder forces bile into the common bile duct, from where it passes through the sphincter of Oddi into the duodenum. The gallbladder is joined to the bile duct by the cystic duct (Figure 1a). The flow of bile between the liver, gallbladder and duodenum is under neurohormonal control. The most common types of gallstones that develop in North American patients are cholesterol gallstones, the formation of which appears to be a phenomenon of the “Western” lifestyle and is related to the supersaturation of cholesterol in bile. Less common types of gallstones include “black” or “brown” stones resulting from hematologic disorders with hemolysis, cirrhosis and chronic infection of the biliary tract.

In many patients, gallstones are an incidental finding on an abdominal ultrasound. If there has been no previous history of symptoms suggestive of gallbladder disease, these patients are said to have asymptomatic gallstones. In general, patients with asymptomatic gallstones do not require treatment.⁴ Clinically overt gallbladder disease can take the form of one of several clinical syndromes: (1) biliary colic; (2) acute cholecystitis; (3) acute gallstone pancreatitis; (4) choledocholithiasis (common bile duct stones); and (5) acute cholangitis (Figure 1b). Although it is a rare condition, we also include a discussion of gallstone ileus in this article because it occurs primarily in the elderly.

Biliary Colic

Biliary colic (sometimes called chronic cholecystitis) is a syndrome characterized by episodic severe epigastric or right upper quadrant abdominal pain that typically occurs in the evenings or nighttime following large fatty meals, and resolves completely within a few hours. Biliary colic is caused by the transient obstruction of the cystic duct from stones inside the gallbladder. In fact, the term biliary colic is actually a misnomer, since most patients perceive the pain as constant rather than “colicky”. An ultrasound of the abdomen shows the presence of gallstones.

Cholecystectomy (removal of the gallbladder) is indicated in patients with a history of biliary colic who have gallstones identified on an abdominal ultrasound. Removal of the gallbladder is not felt to have any major adverse effect on gastrointestinal function. Laparoscopic cholecystectomy is the preferred treatment for gallstones.⁵ Elective laparoscopic cholecystectomy can be done safely in elderly patients, usually as an ambulatory procedure. Under a general anesthetic, four small incisions are made in the abdominal wall, the abdomen is insufflated with carbon dioxide gas, and specialized instruments are used to

Gallstone Disease

remove the gallbladder under video guidance. Most patients are able to return to their usual activities within two weeks of surgery. Major complications or death after cholecystectomy are uncommon, even in patients older than 80 years.⁶ Alternative treatments of gallstones, such as lithotripsy and oral dissolution therapy, are comparatively ineffective and are not commonly used.

Acute Cholecystitis

Acute cholecystitis is similar in presentation to biliary colic, but lasts for a longer period of time (longer than 8–24 hours). Acute cholecystitis is caused by obstruction of the gallbladder or cystic duct by a gallstone, with resulting inflammation of the gallbladder wall. Patients with acute cholecystitis look unwell and may have signs of systemic illness such as fever, nausea and vomiting, and abdominal wall tenderness in the right upper quadrant. These patients may have an elevated white blood cell count and ultrasound findings of a thickened gallbladder wall or free intra-abdominal fluid surrounding the gallbladder.

Most patients with acute cholecystitis are hospitalized and treated with intravenous fluids, antibiotics and analgesics. Most episodes of acute cholecystitis will resolve over a period of several days. If a cholecystectomy is not done during the index hospitalization, it should be delayed for several months following the attack (when much of the inflammation will have resolved). Patients with acute cholecystitis who are treated with an immediate laparoscopic cholecystectomy recover faster, and are discharged from the hospital earlier, than those who do not have immediate surgery.⁷ Although the risk of “conversion” to open surgery is substantially higher in patients who have acute cholecystitis compared to those who have never had cholecystitis, this elevated risk exists even if surgery is delayed and performed electively. Because elderly patients can have gangrene of the gallbladder without appearing seriously ill, early surgery should be considered in all elderly patients with cholecystitis. If the risk of surgery is felt

to be prohibitive in a patient, an ultrasound-guided drainage tube can be placed under local anesthetic to decompress the gallbladder (cholecystostomy tube) in patients who require urgent drainage of the gallbladder.

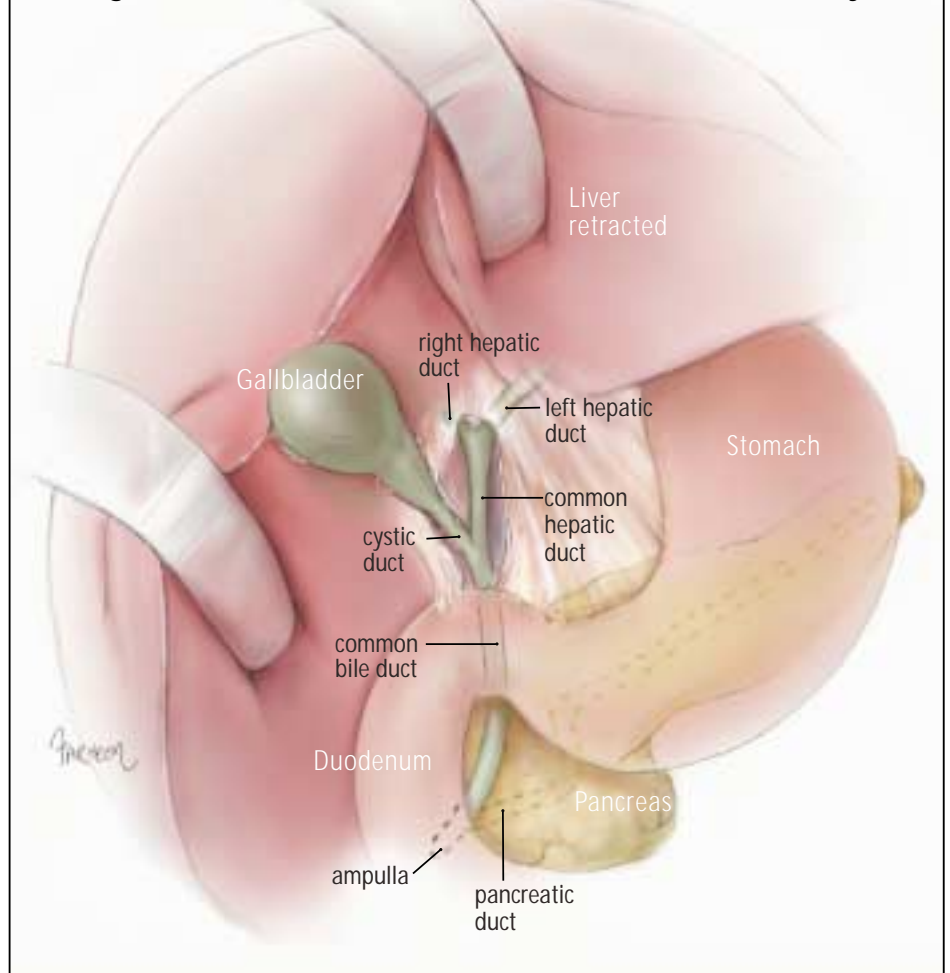
Choledocholithiasis

Choledocholithiasis refers to the presence of gallstones in the bile duct. Among patients with gallstones, the risk of common bile duct stones increases substantially with age. When bile duct stones do not obstruct the bile duct, patients may have symptoms that are indistinguishable from biliary colic, or may even be asymptomatic. Symptoms of choledocholithiasis caused by biliary obstruction include intermittent upper abdominal or back pain and jaundice. Patients may notice dark urine or pale stools, and may be icteric on physical examination. It is

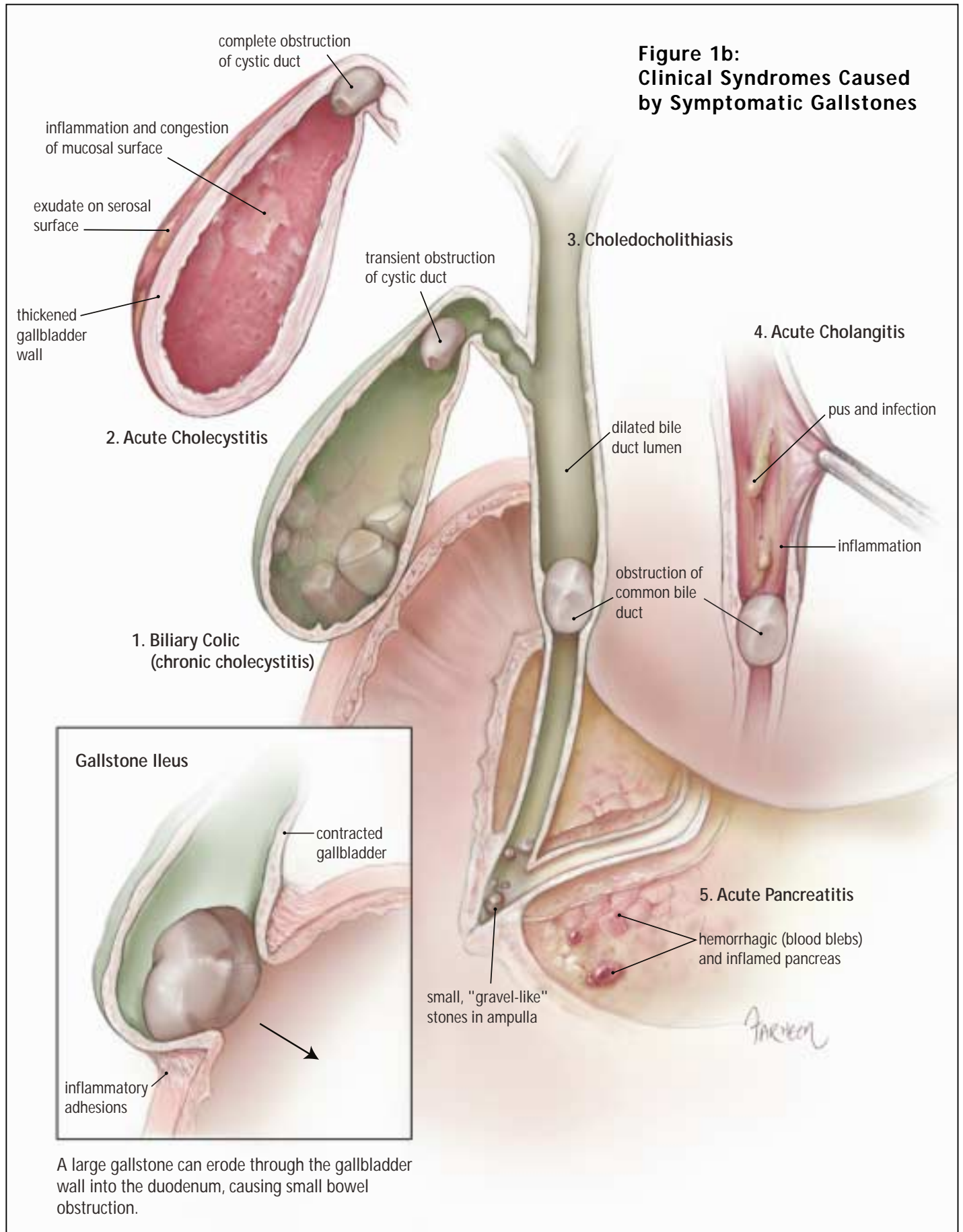
important to exclude malignant causes of obstructive jaundice, such as pancreatic cancer or other periampullary malignancies. Ultrasound of the abdomen usually demonstrates dilated bile ducts, but may not detect the gallstones in the bile duct. Other diagnostic modalities include endoscopic retrograde cholangiopancreatography (ERCP) and, where it is available, magnetic resonance cholangiopancreatography (MRCP). Choledocholithiasis is diagnosed intraoperatively in some patients when an intraoperative cholangiogram is done.

Patients with obstructive jaundice or other evidence suggestive of choledocholithiasis should have an ERCP, with sphincterotomy (division of the sphincter of Oddi) and extraction of the bile duct stones. ERCP is an endoscopic procedure performed under sedation. The most common complication of ERCP—

Figure 1a: The Gallbladder and Associated Anatomy



**Figure 1b:
Clinical Syndromes Caused
by Symptomatic Gallstones**



Summary of Clinical Syndromes of Gallbladder Disease

| Syndrome | Clinical Presentation | Laboratory and Imaging Findings | Recommended Treatment |
|----------------------------|---|---|--|
| Biliary colic | – episodic epigastric or right upper quadrant abdominal pain | – gallstones on ultrasound | – laparoscopic cholecystectomy |
| Acute cholecystitis | – steady epigastric or right upper quadrant abdominal pain lasting longer than 8 hours – right upper quadrant tenderness | – thickened gallbladder wall – gallstones on abdominal ultrasound +/- fluid around gallbladder – leukocytosis | – laparoscopic cholecystectomy (risk of conversion to open surgery is higher than for biliary colic) |
| Choledocholithiasis | – intermittent upper abdominal pain – jaundice | – elevated serum bilirubin and transaminases +/- dilated bile ducts on ultrasound | – endoscopic retrograde cholangiopancreatography (ERCP) with papillotomy and stone extraction – cholecystectomy |
| Cholangitis | – fever – right upper quadrant abdominal pain – jaundice | – elevated serum bilirubin and transaminases, leukocytosis +/- dilated bile ducts on ultrasound | – ERCP with papillotomy or percutaneous transhepatic cholangiography and stone extraction – cholecystectomy |
| Acute biliary pancreatitis | – severe upper abdominal and back pain | – elevated serum amylase or lipase – gallstones or gallbladder sludge on ultrasound | – cholecystectomy shortly after pancreatitis resolves |
| Gallstone ileus | – crampy abdominal pain – nausea – vomiting – abdominal distention | – small bowel obstruction pattern – gas in biliary tree on plain abdominal radiographs | – laparotomy and removal of gallstone from small intestine (enterolithotomy) |

post-ERCP pancreatitis—is actually less common in the elderly than in young patients.⁸ Most patients should have a cholecystectomy after endoscopic sphincterotomy, since gallbladder problems occur in nearly half of patients who are left with an intact gallbladder after an ERCP and stone extraction.⁹

Acute Cholangitis

The presence of stones in the bile duct predisposes patients to bacterial infection of the bile, or acute cholangitis (also called “ascending” cholangitis). Cholangitis is characterized by fever, jaundice and right upper quadrant abdominal pain, and can proceed quickly to septic shock if it is not promptly recognized and treated. Laboratory investigations will typically show leukocytosis, and elevated serum bilirubin and transaminases. Ultrasound of the abdomen will show bile duct dilatation and stones or “sludge” (a suspension of

cholesterol crystals or bilirubinate granules) in the gallbladder.

Patients with cholangitis may be profoundly ill, and initial management should include resuscitation with intravenous fluids and administration of antibiotics. This is followed by emergent decompression of the biliary tract by ERCP with sphincterotomy and stone extraction. If ERCP is not available, or if the patient is unable to tolerate this procedure, the bile duct can be drained externally using a percutaneous transhepatic catheter (PTC) drainage tube placed under ultrasound guidance and under a local anesthetic.

Acute Biliary Pancreatitis

Acute biliary pancreatitis is probably related to small gallstones or biliary sludge¹⁰ in the bile duct that cause dysfunction of the smooth muscle of the sphincter of Oddi, and subsequent inflammation of the pancreas. Patients with acute pancreatitis usu-

ally have severe generalized abdominal and back pain. Between 10% and 20% of patients with acute biliary pancreatitis have severe disease associated with systemic inflammation, organ system dysfunction and a high risk of death. Patients have severe epigastric tenderness on physical examination, and an elevated serum amylase or lipase level.

There is no specific treatment for pancreatitis, and management is directed towards supportive care and prevention of subsequent attacks. Patients with mild-to-moderate disease recover quickly from their pancreatitis, and should have a cholecystectomy prior to their discharge from the hospital. If surgery is contraindicated, an ERCP with sphincterotomy may be done as an alternative to cholecystectomy.¹¹

Gallstone Ileus

Gallstone ileus is mechanical small bowel obstruction caused by one or more large

Gallstone Disease

gallstones that erode through the gallbladder wall into the duodenum. Although it is a rare condition among the general population, gallstone ileus accounts for up to 25% of the cases of nonstrangulated intestinal obstruction in elderly patients.¹² Patients with gallstone ileus commonly present with signs and symptoms of intestinal obstruction (crampy abdominal pain, vomiting, abdominal distention). Plain abdominal radiographs show findings of a small bowel obstruction and gas in the biliary tree (air enters the biliary system through the abnormal communication between the duodenum and gallbladder). Patients with gallstone ileus require an urgent laparotomy with removal of the gallstones impacted in the small intestine (enterolithotomy).

Summary

Gallstone disease is very common in the elderly. The majority of patients who develop symptoms of biliary tract disease have biliary colic, and laparoscopic cholecystectomy is the only treatment required. Occasionally, patients with syndromes such as cholangitis or pancreatitis require other interventions, such as ERCP and sphincterotomy. Both surgery and ERCP can be performed safely in the elderly. Because the elderly tend to present with more severe forms of gallstone disease, and because severe illness may be missed in elderly patients, elderly persons with suspected gallstone disease should be investigated and treated expeditiously. Definitive treatment of gallstones should not be withheld solely due to concern over a patient's age. ♦

No competing financial interests declared.

References

1. McSherry CK, Ferstenberg H, Calhoun WF, et al. The natural history of diagnosed gallstone disease in symptomatic and asymptomatic patients. *Ann Surg* 1985;202:59-63.
2. Attili AF, Capocaccia R, Carulli N, et al. Factors associated with gallstone disease in the MICOL experience. *Hepatology* 1997;26:809-18.
3. Siegel JH, Kasmin FE. Biliary tract diseases in the elderly: management and outcomes. *Gut* 1997;41:433-5.
4. Gracie WA, Ransohoff DF. The natural history of silent gallstones: the innocent gallstone is not a myth. *N Engl J Med* 1982;307:798-800.
5. NIH Consensus Development Panel on Gallstones and Laparoscopic Cholecystectomy. Gallstones and laparoscopic cholecystectomy. *JAMA* 1993;269:1018-24.
6. Brunt LM, Quasenbarth MA, Dunnegan DL, et al. Outcomes analysis of laparoscopic cholecystectomy in the extremely elderly. *Surg Endosc* 2001;15:700-5.
7. Lo CM, Liu CL, Fan ST, et al. Prospective randomized study of early versus delayed laparoscopic cholecystectomy for acute cholecystitis. *Ann Surg* 1988;227:461-7.
8. Freeman ML, DiSario JA, Nelson DB, et al. Risk factors for post-ERCP pancreatitis: a prospective, multicenter study. *Gastrointest Endosc* 2001;54:425-34.
9. Boerma D, Rauws EA, Keulemans YCAC, et al. Wait-and-see policy or laparoscopic cholecystectomy after endoscopic sphincterotomy for bile duct stones: a randomised trial. *Lancet* 2002;360:761-5.
10. Lee SP, Nicholls JF, Park HZ. Biliary sludge as a cause of acute pancreatitis. *N Engl J Med* 1992;326:589-93.
11. Davidson BR, Neoptolemos JP, Carr-Locke DL. Endoscopic sphincterotomy for common bile duct calculi in patients with gall bladder in situ considered unfit for surgery. *Gut* 1988;29:114-20.
12. Cameron JL, editor. *Current surgical therapy*, 7th edition. St. Louis: Mosby, Inc., 2001.